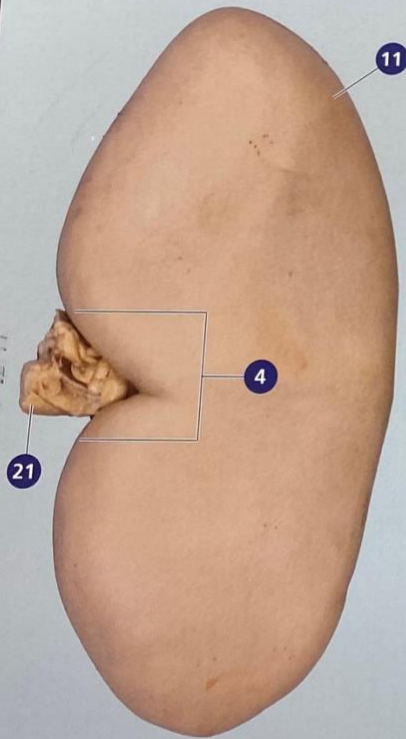


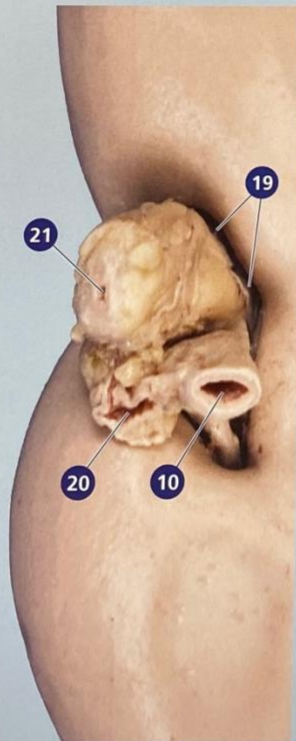
MAMMALIAN KIDNEY

Examine the external features of the kidney.

Carefully make a lateral, longitudinal cut, opening the kidney into two halves. Identify the basic internal structures.



**Anterior view of
left kidney**



Posterior view of hilum

- 1 Arcuate artery*
- 2 Arcuate vein*
- 3 Collecting duct*
- 4 Hilus
- 5 Interlobar artery*
- 6 Interlobar vein*
- 7 Major calyx*
- 8 Minor calyx*
- 9 Nephron*
- 10 Renal artery
- 11 Renal capsule
- 12 Renal column
- 13 Renal cortex
- 14 Renal lobe*
- 15 Renal medulla
- 16 Renal papilla
- 17 Renal pelvis
- 18 Renal pyramid
- 19 Renal sinus
- 20 Renal vein
- 21 Ureter

*Pictured on back

